

A RARE CASE OF A PATIENT WITH A METATYPICAL BASAL CELL CARCINOMA OF THE FOREHEAD TREATED SUCCESSFULLY WITH ELLIPTICAL EXCISION

G. Tchernev¹, J. Ananiev² and J. C. Cardoso³

¹Polyclinic for Dermatology and Venerology, University Hospital Lozenetz, "Saint Kliment Ohridski" University, Sofia, Bulgaria

²Department of General and Clinical Pathology, Medical Faculty, Trakia University, Stara Zagora, Bulgaria

³Dermatology Department, University Hospital of Coimbra, Coimbra, Portugal

Summary: We present a rare case of a 72-year-old patient with an ulcerative lesion localized to the left forehead, appearing 3 months prior to clinical presentation. Biopsy revealed a metatypical basal cell carcinoma. Treatment consisted of wide local excision. There was no sign of recurrence or metastasis after a 12-month follow-up period. Basal cell carcinoma (BCC) and squamous cell carcinoma (SCC) make up 95% of the most common type of cancer in the world, the non-melanoma skin cancer. BCC is known for its potential to be locally invasive, while SCC for its potential to metastasize in lymph nodes. Metatypical basal cell carcinoma (MTBC) is a rare tumor that combines clinical and histopathological features of both BCC and SCC. The gold standard for diagnosis lies in the histopathologic examination. Clinical examination alone does not suffice.

Key words: *metatypical, basal cell carcinoma, histopathology, basosquamous carcinoma, surgery*

INTRODUCTION

Non-melanoma skin cancer is the most common type of cancer in the world. Basal cell carcinoma (BCC) is the most common malignancy of the skin, accounting for 80% of all cutaneous cancers [1, 2]. Risk factors include high cumulative ultraviolet light (UV) exposure, and having Fitzpatrick skin type I or II [3]. BCCs develop from outer root hair follicle epithelium with preference of the head-and-neck region [3, 4]. Loss of function mutations in patched homologue-1 tumor suppressor (PTCH-1) or gain of function mutations activating

PCTH-1 receptor smoothed (SMO) can be identified in the majority of BCCs. One third of BCCs occur in non-sun-exposed areas. Nodular BCC is the most common type of BCC, and classically presents with a raised and rolled border, often with fragility and intermittent bleeding [3, 4].

Metatypical basal cell carcinoma (MTBCC), also referred as basosquamous carcinoma, is a rare variant of BCC, which shares clinical and histopathologic characteristics of both BCC and SCC [5]. MTBCC was first described by MacCormac in 1910 as a histological variant in a series of rodent ulcers, in which basal cell and squamous cell tumors were present side by side without a transition zone [6]. As such, it is considered a particularly aggressive form of BCC, with increased risk of metastases and higher recurrence rates than common BCC. MTBCC can disseminate by perineural invasion and metastasize in up to 5% [7-10]. The terminology of this tumor is still controversial, while the literature data regarding its incidence, pathogenesis, natural course, and optimal treatment are somewhat scarce and not well defined [5].

CLINICAL CASE

Anamnesis. The patient was a 72-year-old Caucasian male with a history of extensive sun exposure who presented with a 4-month history of a lesion on the right forehead (Fig.1a). The lesion was initially painless, and slowly growing, with occasional spontaneous bleeding. Ulceration occurred approximately 1 month after the lesion first appeared.

Clinical examination revealed a 1.8 cm plaque, growing primarily endophytically, with central ulceration, located in the right frontoparietal scalp (Figs 1a, 1b). Multiple surrounding actinic keratoses were present (Figs 1a, 1b).

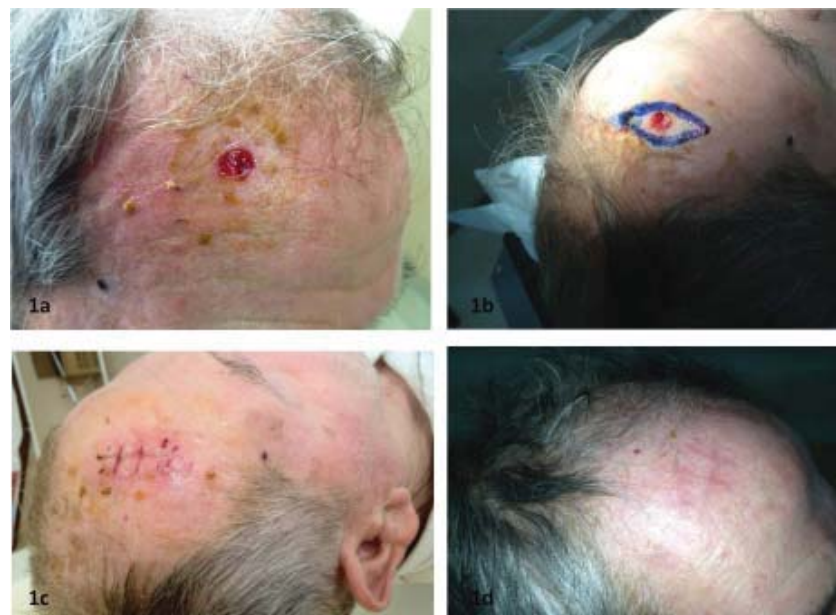

Fig. 1. (a) Ulcerated nodule of the forehead; **(b)** Planning the surgical procedure; **(c)** Appearance after removal of stitches; **(d)** Outcome after 3 months follow-up

Histopathological examination. The tumor islands had a reticulated configuration composed of an incomplete outer layer of dark-staining basal cells and an inner layer, actually representing the majority of the tumor, featuring larger and lighter staining cells (Figs. 2a, 2b, 2c). This can be regarded as an intermediate type of MTBC [9].

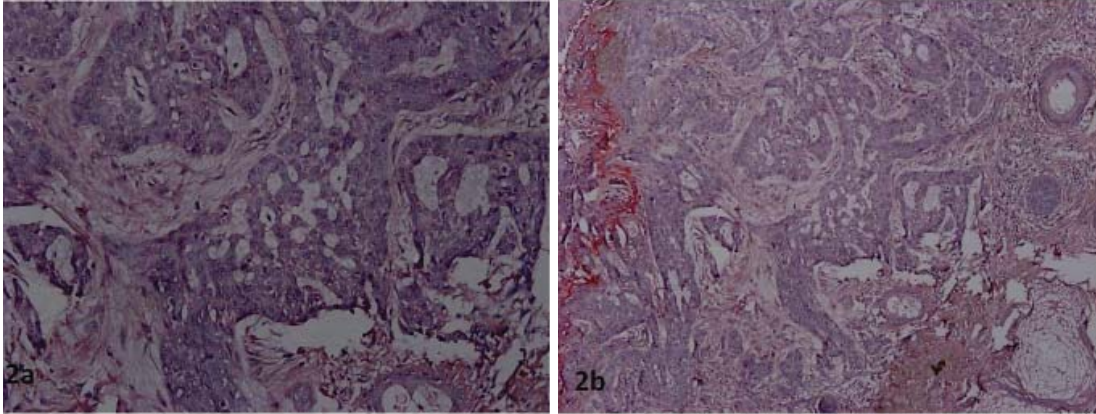


Fig. 2. (a) Trabeculae of tumor cells with a basaloid appearance; **(b), (c)** The cells at the periphery of tumor islands have a more dark-staining appearance, whereas in the center they assume a more pale-staining quality; note the retraction artefact

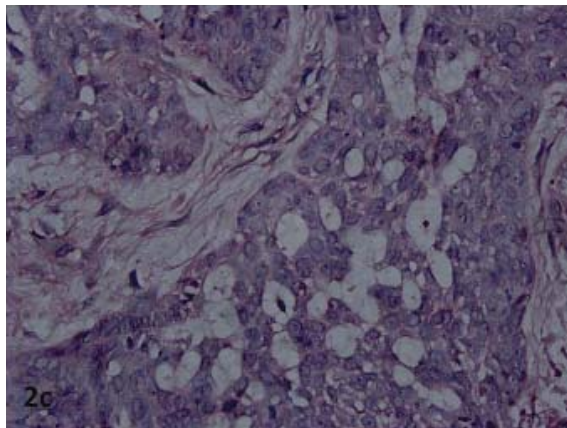


Fig. 2. (c) Detail of the deep part of the tumor, showing the infiltrative growth pattern, in close proximity with the sebaceous glands

Imaging/Laboratory investigations. Chest X-ray, MRI of the head and neck, abdominal ultrasound, sonographic evaluation of the lymph nodes of the neck, axilla, supraclavicular region, and groins did not reveal any gross nodal or visceral metastases.

All routine serum laboratory measurements including complete blood count and liver function tests were normal.

Treatment and Outcome. The tumor was removed with elliptical excision under local anesthesia (Figs. 1a-1d). This was followed by primary closure with single

stitches (Fig. 1d). The postoperative period was uneventful. Stitches were removed on the seventh postoperative day (Fig. 1c). A very good therapeutic and cosmetic result was achieved after the application of Repaderm Gel twice daily for a period of 28 days (Fig. 1d).

DISCUSSION

The term metatypical basal cell carcinoma (MTBCC) or basosquamous carcinoma defines a histopathological variant that comprises features of both basal cell and squamous cell carcinomas, with or without a transition zone between them [9]. Throughout the literature the terms “metatypical” and “basosquamous” are often used interchangeably, although some authors argue that basosquamous carcinoma is more appropriate as reflecting the likely pathogeny of the tumor [10].

MTBCC can be classified histologically into two subtypes: intermediate and mixed [7]. The intermediate-subtype MTBCC is characterized by the presence of tumor lobules or nests composed of basaloid cells that mature into paler cells with more abundant cytoplasm [5, 7]. The mixed-subtype MTBCC is described as having features typical of basal cell carcinoma coexisting with areas of conglomerated squamous cells, and often with the presence of focal keratinization, commonly referred as “squamous pearls” [8, 11]. Both histologically and clinically, MTBCC can be considered a BCC/SCC tumor hybrid [5, 7, 8, 11].

Immunohistochemical analysis is useful in the diagnosis of MTBCC, as areas of basal cell carcinoma are Ber-EP4 and AE1/AE3 positive, while areas of squamous cell carcinoma are AE1/AE3 and CAM5.2-positive, with variable staining with epithelial membrane antigen [13, 14]. The transition zone shows in most of the cases a decline of staining for Ber-EP4a [13, 14].

Recently, Cigna et al. performed a retrospective study of 312 patients with MTBCC localized on face and scalp [15]. They found a strong correlation between mixed subtype and ulceration and intermediate subtype and positive surgical margin. Perineural infiltration is not uncommon among these tumors. They concluded that the intermediate type of MTBCC seems more aggressive [15].

Compared to other types of BCC, MTBCC is considered to have a higher incidence of recurrence and increased incidence of metastasis [5]. Recurrence rate of 10% to 48% have been reported [5, 7, 10, 12, 16]. The metastatic rate can be as high as 5% to 7.4%, what seems to a quantum leap compared to BCC in general with less than one per mille (5, 7, 10, 12, 16). Currently there are no established guidelines regarding the treatment of MTBCC. There is general consensus, that MTBCC should be treated as an aggressive form of BCC [5, 6, 10]. It is recommended that wider surgical margins be taken than for basal cell carcinoma, with Mohs micrographic surgery being an excellent surgical option having lower recurrence rates than classic excision [17]. Mohs is particularly indicated for high-risk locations such as the ears, midface, recurrent or large tumors, and tissue preser-

vation in cosmetically sensitive areas [19]. Close clinical follow-up for 5 years has been recommended.

Vismodegib is an oral inhibitor of the Hedgehog pathway approved by the US Food and Drug Administration. It is the first systemic treatment for patients with locally advanced or metastatic basal cell carcinoma that is not amenable to surgery and radiation [20]. It can be an alternative in MTBCC not treatable by surgery.


CONCLUSIONS

The diagnosis of metatypical basal cell carcinoma requires a thorough medical history and a cutaneous biopsy, followed by exact histopathologic verification, and following appropriate surgical excision. MTBC is regarded as an aggressive form of BCC, with a higher recurrence rate and increased risk of metastasis [7]. This has direct implications for treatment and follow-up of patients.

REFERENCES:

1. Diepgen, T. L. et V. Mahler. The epidemiology of skin cancer. – Br. J. Dermatol., **146**, 2002, Suppl. 61, 1-6.
2. Rubin, A. I., E. H. Chen et D. Ratner. Basal-cell carcinoma. – N. Engl. J. Med., **353**, 2005, № 21, 2262-2269.
3. Mantese, S. A. O., A. L. C. V. Berbert, M. D. A. Gomides et A. Rocha. Basal cell Carcinoma – Analysis of 300 cases. – An Bras Dermatol., **81**, 2006, № 2, 136-142.
4. Kasper, M. et al. Basal cell carcinoma – molecular mimicry and potential new therapies. – J. Clin. Invest., **122**, 2012, № 2, 455-463.
5. Tarallo, M. et al. Metatypical basal-cell carcinoma (MTC) or basosquamous carcinoma (BSC): surgical therapy. – Ann. Ital. Chir., **82**, 2011, № 5, 389-394.
6. MacCormac, H. The relation of rodent ulcer to squamous cell carcinoma of the skin. – Arch. Middlesex Hosp., **19**, 1910, 172-183.
7. Tarallo, M. et al. Metatypical basal cell carcinoma: a Clinical review. – J. Exp. Clin. Cancer Res., **7**, 2008, 27:65.
8. Martin, R. C. 2nd et al. Basosquamous carcinoma: analysis of prognostic factors influencing recurrence. – Cancer, **88**, 2000, № 6, 1365-
9. Garcia, C. et al. Basosquamous carcinoma. – J. Am. Acad. Dermatol., **60**, 2009, № 1, 137-143.
10. Malone, J. P. et al. Basal cell carcinoma metastatic to the parotid: report of a new case and review of the literature. – Ear. Nose Throat. J., **79**, 2000, № 7, 511-5, 518-9.
11. Tarallo, M. et al. Metatypical carcinoma. A review of 327 cases. – Ann. Ital. Chir., **82**, 2011, № 2, 131-135.
12. Kazantseva, I. A., A. N. Khlebnikova et V. R. Babaev. Immunohistochemical study of primary and recurrent basal cell and metatypical carcinomas of the skin. – Am. J. Dermatopathol., **18**, 1996, № 1, 35-42.
13. Beer, T. W., P. Shepherd et J. M. Theaker. Ber EP4 and epithelial membrane antigen and distinction of basal cell, squamous cell and basosquamous carcinomas of the skin. – Histopathology, **37**, 2000, № 3, 218-223.
14. Cigna, E. et al. Metatypical carcinoma of the head: a review of 312 cases. – Eur. Rev. Med. Pharmacol. Sci., **16**, 2012, № 14, 1915-1918.

15. Bowman, P. H. et al. Basosquamous carcinoma. – Dermatol. Surgery, **29**, 2003, № 8, 830-832.
16. Aldred, W. V., V. G. Ramirez et D. H. Nicholson. Intraocular invasion by basal cell carcinoma of the lid. – Arch. Ophthalmol., **98**, 1980, 1821-1822.
17. Cunnenn, T. S., J. L. Yong et R. Benger. Lung metastases in a case of metatypical basal cell carcinoma of the eyelid: an illustrative case and literature review to heighten vigilance of its metastatic potential. – Clin. Experiment. Ophthalmol., **36**, 2008, № 5, 475-477.
18. Leibovitch, I. et al. Basosquamous carcinoma. Treatment with Mohs Micrographic Surgery. – Cancer, **104**, 2005, 170-175.
19. Sakulic, A. et al. Efficacy and safety of vismodegib in advanced basal-cell carcinoma. – N. Engl. J. Med., **366**, 2012, 2171-2179.

✉ *Address for correspondence:*
Assoc. Professor Dr. Georgi Tchernev
Polyclinic for Dermatology and Venerology
Saint Kliment Ohridski University
Medical Faculty
University Hospital Lozenetz
1 Koziak St.
1407 Sofia
Bulgaria
 00359 885 588 424
e-mail: georgi_tchernev@yahoo.de