

ANTEROGRADE FACIAL-SUBMENTAL ARTERY ISLAND FLAP FOR PALATE REPAIR AFTER CARCINOMA ABLATION – A CASE REPORT

Y. Yordanov¹, A. Shef² and J. M. Lasso³

¹Unit of Plastic Surgery and Burns, Military Medical Academy, Sofia

²Department of Dermatovenereology and Allergology, Military Medical Academy, Sofia

⁴Unit of Plastic Reconstructive and Aesthetic Surgery, University Hospital Gregorio Marañón, Madrid, Spain

Summary. The submental island flap is a reliable alternative in the armamentarium of the plastic surgery for reconstruction of various head and neck defects including those affecting the oral mucosa and the palate. Since it was first described, it has been affirmed as a safe, rapid and easy reconstruction method with minimal to missing donor site morbidity. We present a clinical case of complete reconstruction of soft palate using an anterograde pattern submental flap. We believe this flap to be safer than the reverse-flow one that has been typically used for defects located in this region. The surgical technique is described.

Key words: *anterograde submental flap, flap harvest technique, soft palate reconstruction*

INTRODUCTION

The oropharyngeal reconstruction after resection of a cancer is a highly challenging and complex surgical initiative. Grafts, regional flaps and free tissue transfer can be employed in the restoration of integrity and function after ablative surgery. Ideally, the tissue used should be reliable, of sufficient size with minimum donor site morbidity and functionally and cosmetically acceptable [1-3].

The submental island flap is an axial patterned flap based on the submental artery [1, 4, 5] which is a constant and well defined branch of the facial artery arising 5 to 6.5 cm from its origination (Fig. 1) [3, 4]. It arises deep to the submandibular gland, then runs in a groove on the medial aspect of the gland and is bounded

medially by the mylohyoid muscle and above by the mandibular border. It may be superficial (30%) or deep to the digastric muscle (70%) [6], and ends behind the symphysis of the mandible on the anterior belly of the digastric muscle, from where it sends branches to the lower lip and sublingual gland. The submental artery gives off four types of collateral vessels [4, 5]: 1) short branches to the submandibular gland; 2) muscular branches to the platysma, digastric, and mylohyoid muscles; 3) small branches to the subplatysmal fatty layer; and 4) cutaneous perforations ranging from one to four in number, with one perforator piercing the platysma and dividing into many branches in the subdermal plane. These branches anastomose extensively with the contralateral branches and thus supply almost the entire neck skin with reliable random perfusion of the contralateral part of the neck [6]. The venous drainage of the flap is provided by the submental vein draining into the facial vein, and there is at least one anastomosing vein between the facial and external jugular veins [4].

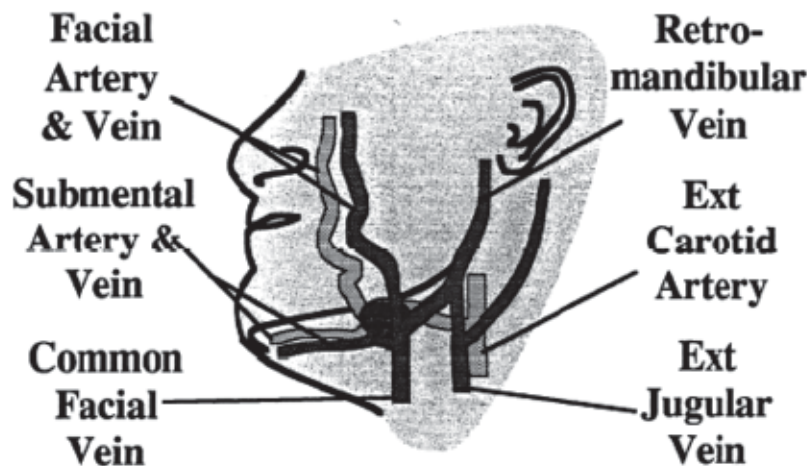


Fig. 1. Vascular anatomy of the submental island flap

Submental artery island flap is an increasingly popular option for head and neck reconstruction including intraoral defects [7]. It can be used as a cutaneous, myocutaneous, fasciocutaneous or osteocutaneous flap. The facial-submental artery island flap has two subtypes: the anterograde pattern and the reverse-flow pattern. The point of the advantages and disadvantages of one kind to another has given rise to much controversy [8, 9]. We present a complete reconstruction of soft palate using an anterograde submental flap, which is safer than the reverse-flow one that has been typically used for defects located in this region.

REPORT OF THE CASE

A 68-year-old male ex-smoker of 60 cigarettes daily to 2 years before was seen by our team in the General University Hospital Gregorio Marañón in Madrid,

Spain, because of a 1-year history of oropharyngeal moderately differentiated invasive squamous cell carcinoma which was treated with radiotherapy (total of 7000 cGy) and chemotherapy (Cetuximab[®]). On examination, after these treatments the patient had an arch asymmetry with ulcerated lesion that affected the left side wall of the oropharynx respecting the tongue and extending along the soft palate to the level of the hard palate laterally and to the uvula in the midline. Physical examination did not reveal cervical adenopathy. A computed tomography scan showed a small necrotic ipsilateral submandibular lymphadenopathy. The patient was offered surgery and consent was obtained after full explanation of the surgical procedure, the likely outcome and the potential complications that may occur.

The patient presented also a history of a coronary artery disease, percutaneous transluminal coronary angioplasty and stent placement 5 years ago, restenosis and new stent placement 4 years afterwards, haemorrhagic cerebral vascular accident and bilateral pulmonary thromboembolism, poorly controlled metabolic syndrome and a stable thoracoabdominal aortic aneurysm.

SURGICAL TECHNIQUE

Under general anesthesia, the patient underwent resection of the involved palate, alveolus, and buccal mucosa. The defect measured 5 x 8 cm and communicated with the antrum. The intraoperative examination of the lymph nodes within the submental region did not reveal pathologic adenopathy.

A 5 x 9 cm ellipse of skin was outlined in the submental area across the midline with the patient's head extended in a supine position (Fig. 2). The anterior extent of the incision was placed 1.8 cm behind the mandibular margin in order to prevent retraction of the lower lip during donor site closure and to optimize camouflaging the scar. The flap was raised meticulously from the contralateral to ipsilateral pedicle side with the platysma muscle included. A dissection was made close to the submandibular gland with ligation of the branches from the submental artery. The upper half of the gland was skirted. The facial and submental arteries were exposed and the marginal mandibular nerve was identified and carefully preserved in the fatty tissue underneath the platysma muscle. The opposing submental artery and vein were then ligated. The ipsilateral anterior belly of the digastric muscle was detached from the hyoid bone and included in the flap in order to protect the terminal flap vessels. The dissection demonstrated the origin of the submental artery at 5 cm to the origination of the facial artery. Submandibular and facial veins then were dissected to their origins and a strip of the mylohyoid muscle was included in the flap. The submental pedicle was completely skeletonized and the facial source vessels were divided distally to the submental vessels. The harvested flap was passed through a generous submucous-subcutaneous tunnel from the buccal mucosa adjacent to the palatal defect to the superior aspect of the submandibular incision. The skin paddle was then carefully passed through the submucous-subcu-

taneous tunnel into the oral cavity (Fig. 3). Absorbable sutures were used to secure the submental skin into the palatal defect. The donor site defect was closed primarily by undermining of the inferior skin flaps and advancing these flaps to achieve a primary closure with the patient's neck in extension in order to avoid hypertrophic scarring. Penrose drainage was put in place for 2 days. The patient tolerated the procedure without any intraoperative complications.

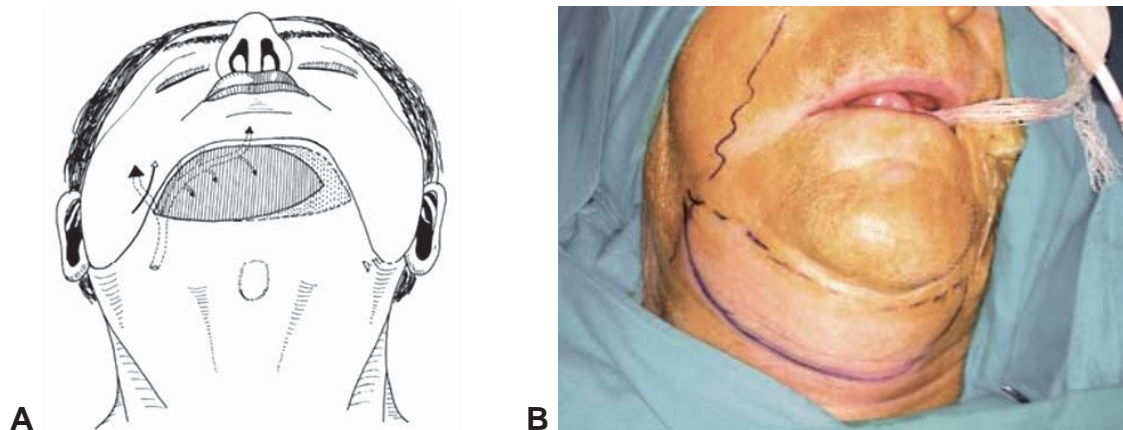


Fig. 2. Design of the flap. (A) Outlining the flap. (B) Note the excess skin and subcutaneous fatty tissue in the submental zone- it facilitates the flap dissection and the donor site closure afterward

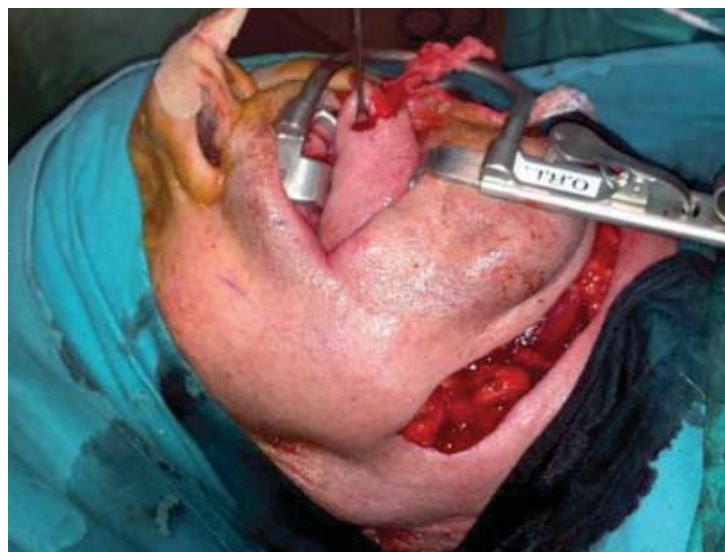

Fig. 3. Flap is dissected and passed through a tunnel from the origin of the pedicle into the oral cavity

On the 3rd postoperative day the patient suffered an acute non-Q-wave myocardial infarction. With drug therapy the patient's condition was brought under control and no significant consequences were observed. The patient was started on a liquid oral diet on postoperative day 4 and advanced to a regular diet on day 6.

One month postoperatively, a good reconstructive result in terms of anatomy and function was presented (Fig. 4). The donor site was healed with minimal cosmetic deformity (Fig. 5).

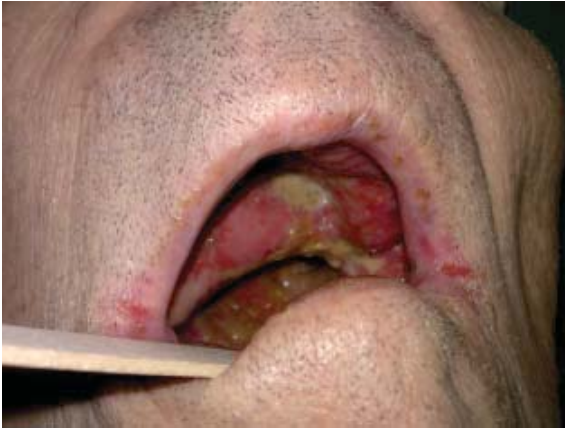

Fig. 4. The reconstructed palate 1 month after the surgery

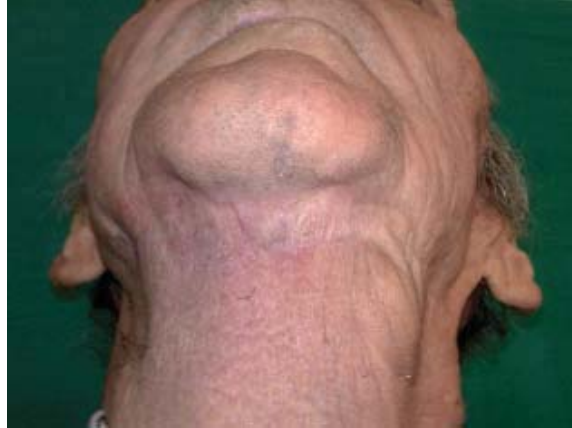

Fig. 5. The donor site scar 1 month after the surgery

DISCUSSION

The facial-submental artery island flap is reported to be a simple and reliable flap for reconstruction of oropharyngeal defects following oncological resections [1-5]. It was first described by Martin et al [4] in 1993, as a variation of the random submental flap described earlier by Jellouli et al [10]. Unlike Jellouli et al's random cervical flap, the submental island flap is based on an axial pattern blood supply (submental artery and vein), thereby improving the reliability and mobility of the submental skin paddle. The submental artery island flap is an increasingly popular option for head and neck reconstruction including the tongue, glottic larynx, cervical esophagus, and cutaneous defects [1-4, 11]. As stated by Pistre et al [12], this flap could be an alternative after the unsatisfactory results from local flaps reconstruction and the long surgery times needed for any microsurgical procedure.

The submental flap has many advantages: 1) the vascular pedicle is constant, and its caliber allows microsurgical transfer too; 2) it is reliable, versatile, and can be raised rapidly (when no additional pedicle dissection is required); 3) the donor site is inconspicuous, with the scar on the innerside of the curve of the mandible; 4) the arc of rotation is wide and the flap reaches the whole of the ipsilateral face, homolateral cervical region, oropharynx, and the whole oral cavity; 5) color match and tissue texture are close to those of the face; 6) in male patients, the bearded area can cover where the defect lies; 7) correction of submental rhytides and adiposity, when they exist, is possible; 8) the skin paddle can be large in older patients.

The disadvantages of this flap include: 1) possible damage to the marginal mandibular branch of the facial nerve, especially when the dissection starts by the incision of the upper part of the skin paddle; 2) in male patients, hair growth on

the skin paddle may be a problem requiring future treatment when reconstruction of a non-bearded area is considered (e.g., intraoral defect); 3) dissection requires thorough anatomic knowledge of the region and should be performed after extensive laboratory training; 4) dissection must be careful, and the anterior belly of the digastric muscle must be raised with the flap to improve blood supply to the contralateral side; 5) this flap cannot cover carcinoma defects when lymphatic drainage is in the submandibular compartment (malignant tumors can involve lymph nodes to the flap or in its pedicle).

Submental flap can be used as a cutaneous, myocutaneous, fasciocutaneous or osteocutaneous flap. One of the outstanding features of the flap is its excellent reach and mobility when is based on a retrograde pedicle as a reverse-flow flap. This has proved especially advantageous for reconstruction of mobile structures such as the tongue.

Furthermore, a large paddle of the relatively thin skin over the submental area can be harvested. Karacal et al [13] reported using flaps between 4 x 6 and 6 x 8 cm for the reverse pattern of the flap and found that these surpassed other flaps for reconstructing large periorbital soft tissue defects and the socket. Daya et al [14] believed that a skin paddle as large as 7 x 14 cm could be harvested. A skin paddle up to 7 x 18 cm may be possible, depending on the laxity of the submental skin [4]. In our clinical experience the largest submental flap that has been applied was 6 x 12 cm for reconstruction of the floor defect of the oral cavity but we are concerned that the flap dimensions must be individualized to each patient based on the laxity that dictates the amount of skin that can be harvested without compromising a primary closure. Regardless of the flap size, the skin paddle should be designed in an elliptical fashion to facilitate primary closure.

In this clinical report, we present a case of intraoral reconstruction using an anterograde island submental flap. The submental artery originated too distally and initially seemed unacceptable the flap to be designed in anterograde pattern. With an accurate dissection of the submandibular and facial veins down to their origins we obtained a maximal pedicle length. From the other hand, by including a strip of the mylohyoid muscle, we achieved a complete flap mobilization. After these two simple technical steps the flap pedicle length and the arc of rotation were sufficient to reach the roof of the oropharynx. Dissection over the mandible maintaining soft tissues as a block was a principal condition to reach the palate.

We consider the anterograde technique appropriate and more anatomical, determined only by the facial artery without the dependence of its anastomotic relationships [15] and independent of the valvular anatomy of the facial vein [3]. Although we are encouraged for the future application of the submental flap in our practice, we do not recommend the use of this flap in cases with established nodal disease in the neck or when it is impossible to exclude their presence.

REFERENCES

1. P a r m a r , P. S. et D. P. Goldstein. The submental island flap in head and neck reconstruction. – Curr. Opin. Otolaryngol. & Head Neck, **17**, 2009, 263-266.
2. M u l t i n u , A. et al. The submental island flap in head and neck reconstruction. – Int. J. Oral. Maxillofac. Surg., **36**, 2007, 716-720.
3. S t e r n e , G. D. et al. The submental island flap. – Br. J. Plast. Surg., **49**, 1996, № 2, 85-89.
4. M a r t i n , D. et al. The submental island flap: a new donor site. Anatomy and clinical applications as a free or pedicled flap. – Plast. Reconstr. Surg., **92**, 1993, 867-873.
5. M a g d e n , O. et al. Anatomic study of the vasculature of the submental artery flap. – Plast. Reconstr. Surg., **114**, 2004, 1719-1723.
6. T a n , O., B. Atik et D. Parmaksizoglu. Soft tissue augmentation of the middle and lower face using the deepithelialized submental flap. – Plast. Reconstr. Surg., **119**, 2007, 873-879.
7. S e b a s t i a n , P. et al. The submental island flap for reconstruction of intraoral defects in oral cancer patients. – Oral Oncol. **44**, 2008, 1014-1018.
8. Z h a n g , B. et al. Reverse facial–submental artery island flap for reconstruction of oropharyngeal defects following middle and advanced-stage carcinoma ablation. – Br. J. Oral Maxillofac. Surg., **49**, 2011, 194-197.
9. C h e n , W. L. et al. Submental flap for reconstructing tongue defect with V–Y advancement flap for repairing submental defect. – Otolaryngol. Head Neck Surg., **141**, 2009, 202-206.
10. J e l l o u l i , M. et al. Choice of methods for reconstruction of the cheek after carcinologic excision based on a retrospective study of 32 cases in 8 years from 1980 to 1987 at the Gustave Roussy Institute. – Ann. Otolaryngol. Chir. Cervicofac., **107**, 1990, 265-269.
11. Y i l m a z , M., A. Menderes et A. Barutcu. Submental artery island flap for reconstruction of the lower and mid face. – Ann. Plast. Surg., **39**, 1997, 30-35.
12. P i s t r e , V. et al. The submental flap: its uses as a pedicled or free flap for facial reconstruction. – Clin. Plast. Surg., **28**, 2001, № 2, 303-309.
13. K a r a ç a l , N. et al. Reverse-flow submental artery flap for periorbital soft tissue and socket reconstruction. – Head Neck, **28**, 2006, 40-45.
14. D a y a , M., O. Mahomva et A. Madaree. Multistaged reconstruction of the oral commissures and upper and lower lip with an island submental flap and a nasolabial flap. – Plast. Reconstr. Surg., **108**, 2001, № 4, 968-971.
15. M i d y , D. et al. A contribution to the study of the facial artery, its branches and anastomoses; application to the anatomic vascular bases of facial flaps. – Surg. Radiol. Anat., **8**, 1986, № 2, 99-107.



Address for correspondence:

Yordan Petrov Yordanov, MD, PhD
Unit of Plastic Surgery and Burns
Military Medical Academy – Sofia, Bulgari
3, Georgy Sofiisky Blvd.

1606 Sofia



+359 887 56 00 54

e-mail: yordanov_vma@abv.bg