

# CLINICAL ASSESSMENT AND MOLECULAR GENETICS OF AN AUTOSOMAL DOMINANT RETINITIS PIGMENTOSA IN A BULGARIAN ROMA FAMILY

K. Koev<sup>1</sup>, S. Cherninkova<sup>2</sup>, Ch. Chakarova<sup>3</sup>, R. Georgiev<sup>1</sup>, S. Dimitrova<sup>4</sup>, R. Kaneva<sup>5</sup> and S. Bhattacharya<sup>3</sup>

<sup>1</sup>Department of Ophthalmology, MU – Sofia, Bulgaria

<sup>2</sup>Department of Neurology, University Hospital “Alexandrovska”, Sofia, Bulgaria

<sup>3</sup>Department of Genetics, Institute of Ophthalmology, UCL, London, UK

<sup>4</sup>Molecular Medicine Center, MU – Sofia, Bulgaria

<sup>5</sup>Molecular Medicine Center and Department of Medical Chemistry and Biochemistry, MU – Sofia, Bulgaria

**Summary.** Purpose was to make a clinical assessment and molecular genetic analysis in patients with autosomal dominant form of retinitis pigmentosa (adRP) in a Bulgarian Roma family. Clinical assessment and genealogical analysis in a Bulgarian Roma family suggested the presence of RP with autosomal dominant inheritance with at least 12 affected in 4 generations. Clinical results showed best corrected visual acuity. Performed were kinetic Goldmann perimetry; direct and indirect ophthalmoscopy; ERG; fluorescein angiography. The molecular genetic analysis involved screening of 15 known adRP genes using microarray panel of Asper Biotech in the index patient. T in exon 4 of the RP1 gene, leading to an amino acid substitution T373I was found in heterozygous condition. Conclusion should adRP is a severe and genetically heterogeneous retinal degeneration. We present a Bulgarian Roma family with typical clinical symptoms of RP and heterozygous change in the RP1 gene, which has previously been described as a possible disease causing mutation in a Pakistani family with adRP and in homozygous condition leading to a severe arRP in 2 consanguineous families of Pakistani origin. The clinical and genetic analysis of additional affected and unaffected family members is ongoing. This will allow better genotype-phenotype correlations to be made.

**Key words:** *autosomal dominant retinitis pigmentosa, molecular genetic analysis, tunnel visual field, ERG, fluorescein angiography*

## INTRODUCTION

**R**etinitis pigmentosa (RP) is a type of progressive retinal dystrophy, a group of inherited disorders in which abnormalities of the photoreceptors (rods and cones) or the retinal pigment epithelium (RPE) of the retina lead to progressive visual loss [1].

Clinical variability and genetic heterogeneity have an important impact on genetic testing and counselling of affected families. RP is a group of inherited progressive retinal diseases affecting about 1 in 3500 people worldwide.

Linkage mapping in a large, seven-generation family with type 2 autosomal dominant retinitis pigmentosa (ADRP) demonstrates linkage between the disease locus (RP1) and DNA markers on the short arm of human chromosome 8 [2, 3, 4].

**Purpose:** To make a clinical assessment and molecular genetic analysis in patients with autosomal dominant form of retinitis pigmentosa (adRP) in a Bulgarian Roma family.

## MATERIAL AND METHODS

Clinical assessment and genealogical analysis in a Bulgarian Roma family suggested the presence of RP with autosomal dominant inheritance with at least 12 affected in 4 generations.

Best corrected visual acuity; kinetic Goldmann perimetry; direct and indirect ophthalmoscopy; ERG; fluorescein angiography.

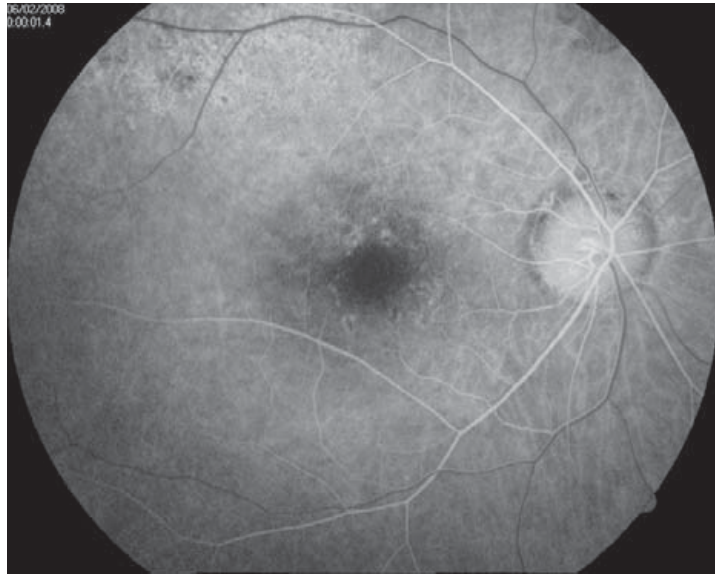
The molecular genetic analysis involved screening of 15 known adRP genes using microarray panel of Asper Biotech in the index patient.

## CLINICAL RESULTS

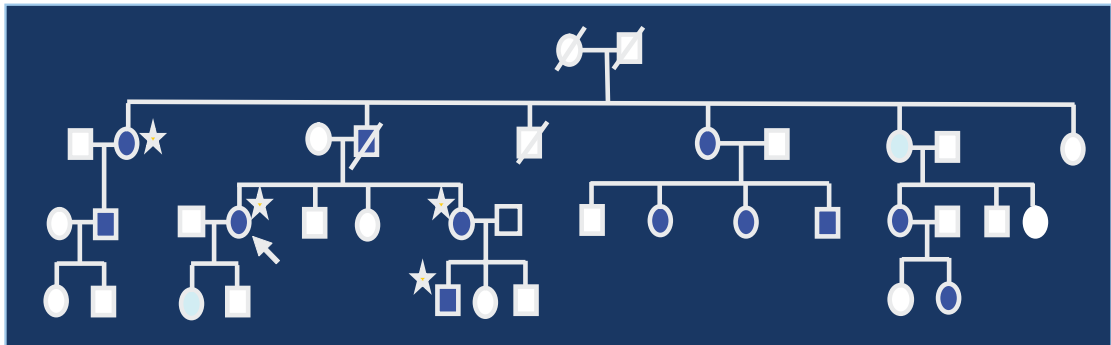
We found the following symptoms in the 8 examined patients from the family:

1. The onset of the first visual complaints ranged from 7-8 years.
2. Bilateral symmetrically reduced visual acuity in the range between 0.01 till 0,3.
3. Bilateral tunnel visual field and central/paracentral scotomas.
4. Dustlike and granular pigmentation in the macular area and midperiphery.
5. RPE atrophy and optic disc pallor.
6. In all patients, the ERG are non detectable as well under red and blue filter.
7. Fluorescein angiography showed an atrophy of the RPE in the macular area and midperiphery.

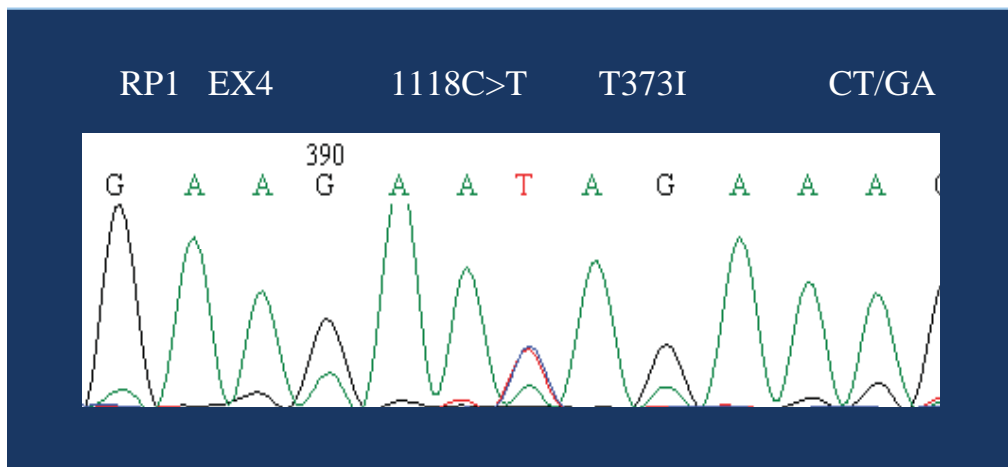
### Fluorescein angiography of the proband



### Molecular genetic results



The mutation 1118C > T in exon 4 of the RP1 gene, leading to an amino acid substitution T373I was found in heterozygous condition in the proband



## DISCUSSION

Retinitis pigmentosa is a frequent retinal dystrophy characterized by a progressive loss of photoreceptors along with retinal degeneration [5]. RP1 gene mutations are the second most common cause of autosomal dominant retinitis pigmentosa [3].

As phenotypes do not always correlate with the respective genotypes, it is of utmost importance that clinicians, geneticists, counsellors, diagnostic laboratories and basic researchers understand the relationships between phenotypic manifestations and specific genes, as well as mutations and pathophysiologic mechanisms [6].

Dominant RP caused by mutations in the RP1 gene often shows late onset of the disease phenotype, usually by the third decade of life. Pierce et al. [7] observed that patients suffering from adRP who were heterozygous for the RP1 mutation had classic, less severe adRP phenotype with late onset of disease.

The adRP is a severe and genetically heterogeneous retinal degeneration. We present a Bulgarian Roma family with typical clinical symptoms of RP and pigmentation in the macular area.

The molecular genetic analysis of the known adRP genes led to the identification of heterozygous change in the RP1 gene (**1118C>T,T373I**), which has previously been described as a possible disease causing mutation in a Pakistani family with adRP and in homozygous condition leading to a severe arRP in 2 consanguineous families of Pakistani origin [8].



The study [9] provides the first report of involvement of mutations in the RP1 gene in the autosomal recessive RP phenotype. All three recessive Pakistani families presented here showed the severe form of RP with early onset [9].

The clinical and genetic analysis of additional affected and unaffected family members is ongoing. This will allow better genotype-phenotype correlations to be made.

## REFERENCES:

1. Hartong, D. T., E. L. Berson et T. P. Dryja. Retinitis pigmentosa. – *Lancet*, **368**, 2006, № 9549, 1795-1809.
2. Blanton, S. H. et al. Linkage mapping of autosomal dominant retinitis pigmentosa (RP1) to the pericentric region of human chromosome 8. – *Genomics*, **11**, 1991, № 4, 857-869.
3. Payne, A. et al. RP1 protein truncating mutations predominate at the RP1 adRP locus. – *Invest. Ophthalmol. Vis. Sci.*, **41**, 2000, № 13, 4069-4073.
4. Berson, E. L. et al. Clinical features and mutations in patients with dominant retinitis pigmentosa-1 (RP1). – *Invest. Ophthalmol. Vis. Sci.*, **42**, 2001, № 10, 2217-2224.
5. Adhi, M. R., Y. Jafri et S. Hussain. Molecular confirmation of the causes of inherited visual impairment in Northern Pakistan. – *J. Coll. Physicians Surg. Pak.*, **19**, 2009, № 12, 806-808.

6. Bell, J. Predicting disease using genomics. – Nature, **429**, 2004. 453-456.
7. Pierce, E. A. et al. Mutations in a gene encoding a new oxygen-regulated photoreceptor protein cause dominant retinitis pigmentosa. – Nat. Genet., **22**, 1999, 248-254.
8. Riazuddin, S. A. et al. Autosomal recessive retinitis pigmentosa is associated with mutations in RP1 in three consanguineous Pakistani families. – Invest. Ophthalmol. Vis. Sci., **46**, 2005, No 7, 2264-2270.
9. Khaliq, S. et al. Novel association of RP1 gene mutations with autosomal recessive retinitis pigmentosa. – J. Med. Genet., **42**, 2005, 436-438.

 *Adress for correspondence:*  
Assoc. Prof. Krassimir Koev, PhD  
Medical University Sofia  
2 Zdrave str.  
Sofia  
 8365504